

PATHOPHYSIOLOGY & MANAGEMENT OF TRAUMATIC CERVICAL SPINE INJURY

PATHOPHYSIOLOGY

- ◎ **25% cervical trauma occurs in the upper cervical spine.**
- ◎ **Most commonly involving the axis, comprising up to 20% of cervical spine injuries.**
- ◎ **Atlas fractures occur in 3 – 13% of patients.**
- ◎ **C 3 fractures occur in less than 10 of patients.**

Representative Angles (Degrees) of Rotation of the Cervical Spine

INTERSPACE	TYPE OF MOTION		
	Combined Flexion / Extension (x-Axis Rotation)	One side Lateral Bending (y-Axis Rotation)	One side Axial Rotation (z-Axis Rotation)
<u>UPPER</u>			
Ocp – C 1	13	8	0
C 1 – C 2	10	0	47
C 2 – C 3	10	10	3
<u>MIDDLE</u>			
C 3 – C 4	15	11	7
C 4 – C 5	20	11	7
C 5 – C 6	20	8	7
<u>LOWER</u>			
C 6 – C 7	17	7	6
C 7 – T 1	9	4	2

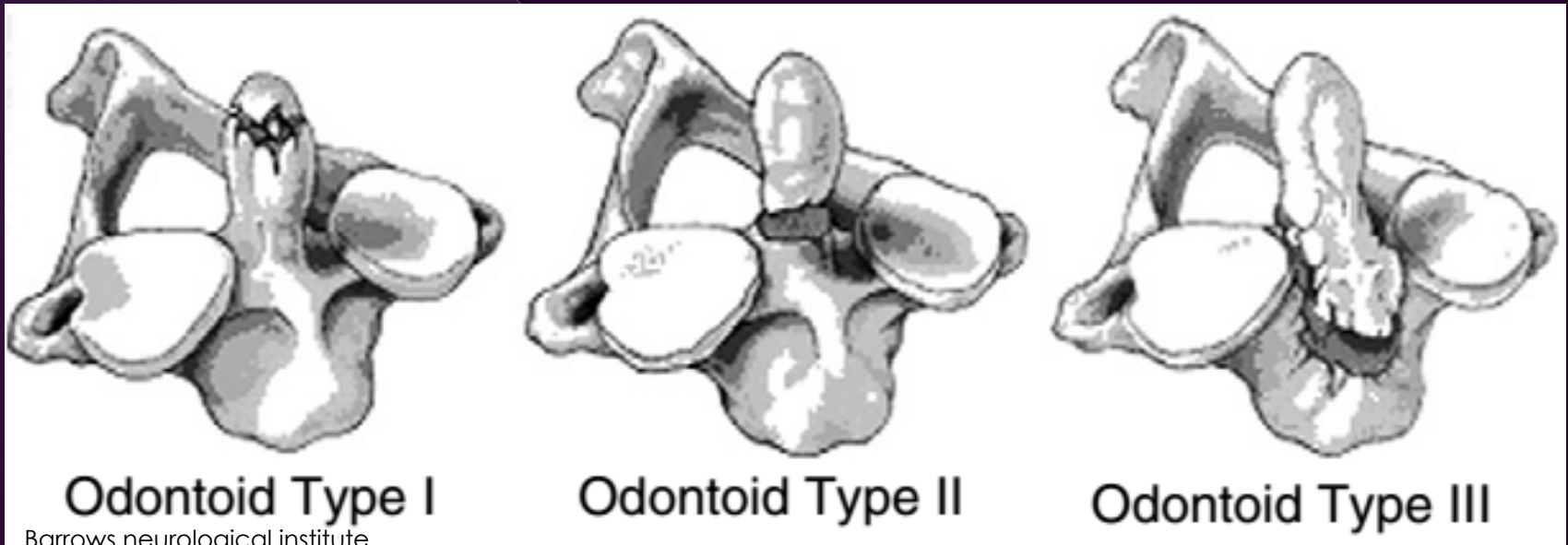
** Source: From White and Panjabi*

CLASSIFICATION

UPPER CERVICAL TYPE	FEATURES	MECHANISM
OCCIPITOCERVICAL DISLOCATION		
TYPE I	Ant. dislocation of condyle on C1 lat. Mass	Ant. Translation with slight distraction
TYPE IIA	Vertical distraction of C0– C1 joint > 2 mm	Axial/vertical distraction
TYPE IIB	Vertical distraction of C1– C2 joint > 2 mm	Axial/vertical distraction
TYPE III	Wedge shaped avulsion fracture of condyle by alar ligament, usually unilateral	Posterior translation with slight distraction
OCCIPITAL CONDYLE FRACTURE		
TYPE I	Unilateral impacted fracture	Axial load with slight lateral bend
TYPE II	Same as Type I with basilar or occipital fracture, or bilateral condyle fractures	Severe axial load with lateral load
TYPE III	Wedge shaped avulsion fracture	Lateral bend with rotation

UPPER CERVICAL TYPE	FEATURES	MECHANISM
ATLAS FRACTURES		
Posterior Arch Fractures	Isolated fracture of posterior arch	Hyperextension with axial load
Ring Fracture (Jefferson Fracture)	Fracture of both posterior & anterior arches	Axial load
Lateral Mass Fracture	Isolated fracture of C1 lat. mass	Axial load with lateral bending
Avulsion Fracture	Avulsion fracture of medial lat. Mass by transverse ligament	Axial load or C1-C2 translation
ODONTOID FRACTURES		
TYPE I	Avulsion fracture of dens tip by alar ligament	Lateral bend with rotation
TYPE II	Complete fracture through the odontoid base	Hyperflexion
TYPE IIA	Type II with marked comminution	Hyperflexion
TYPE III	Fracture of C2 body	Hyperflexion

DIAGRAM SHOWS THE TYPES OF ODONTOID FRACTURE



UPPER CERVICAL TYPE	FEATURES	MECHANISM
C2 PARS INTERARTICULARIS FRACTURE (HANGMAN'S)		
TYPE I	Fracture at pars with < 3mm translation & no angulation	Hyperextension with compression
TYPE II	Pars fracture with > 3 mm translation & significant angulation	Hyperextension with axial load followed by translation & deceleration
TYPE IIA	More angulation, less translation than Type II	Flexion distraction
TYPE III	Type I fracture with facet dislocation	Flexion distraction followed by extension
ATLANTO AXIAL SUBLUXATION		
LIGAMENTOUS	Ruptured transverse ligament	Flexion with ant. Translation or axial load
ROTATIONAL TYPES (I to IV)	Unilateral subluxation of C1 on C2	Rotation with ligamentous laxity

CLASSIFICATION OF THE LOWER CERVICAL SPINE INJURY (C3 – C7)

Injuries to the lower cervical spine are major traumas and frequently occur in combination with neurological complications.

How are the fractures of the lower cervical spine classified?

Based on the AO classification system, Aebi introduced a classification system for fractures of the lower cervical spine (C3-C7) that refers to the anterior column (vertebral body and intervertebral disc) and the posterior elements of the vertebra (vertebral joints and ligamentous apparatus).

TYPES OF LOWER CERVICAL SPINE FRACTURES

Type A -anterior column fractures:

⦿ **A1: Solely or primarily bony injury**

A1.1: Uniform compression

A1.2: Marginal fracture without visible ligament injury

A1.3: Wedge fracture without visible ligament injury

TYPES OF LOWER CERVICAL SPINE FRACTURES

○ A2: Osteoligamentous lesion

A2.1: Vertebral body fracture, multifragmentary, one upper plate affected, 1 intervertebral disc injured

A2.2: A2.1 + 2 intervertebral discs affected

A2.3: Fragmented fracture, posterior wall dislocated by less than 3 mm, posterior elements not visibly injured

TYPES OF LOWER CERVICAL SPINE FRACTURES

⦿ A3: Solely or primarily ligamentous lesion

A3.1: Rupture of the anterior longitudinal ligament and intervertebral disc

A3.2: Traumatic disc hernia

TYPES OF LOWER CERVICAL SPINE FRACTURES

- Type B fractures -posterior element fractures:

B1: Solely or primarily osseous lesion

B1.1: Isolated fracture of the posterior elements

- (1) Spinous process
- (2) Arch
- (3) Both

B1.2: Fracture of the small vertebral joints without dislocation

- (1) Unilateral
- (2) Bilateral

B1.3: Combination of B1.1 and B1.2

- (1) Spinous process
- (2) Arch
- (3) Both

TYPES OF LOWER CERVICAL SPINE FRACTURES

B2: Osteoligamentous lesion

B2.1: Fracture of posterior elements with subluxation

- (1) Spinous process**
- (2) Arch**
- (3) Both**

B2.2: Facet fracture (shearing) + subluxation of adjacent facets

- (1) Unilateral**
- (2) Bilateral**

TYPES OF LOWER CERVICAL SPINE FRACTURES

B3: Solely or primarily ligamentous lesion

B3.1: Rupture of the posterior ligamentous complex with subluxation in the vertebral joints (bilateral)

B3.2: Rupture of the posterior ligamentous complex with asymmetrical subluxation in the vertebral joints (unilateral)

TYPES OF LOWER CERVICAL SPINE FRACTURES

- **Type C fractures - affect both the anterior column and the posterior elements:**

C1: Solely or primarily osseous lesion

C1.1: Burst fracture of the vertebral body in combination with burst fracture of the posterior elements (arch, spinous process)

C1.2: Horizontal fracture through vertebral body with burst of the posterior elements (arch, spinous process)

TYPES OF LOWER CERVICAL SPINE FRACTURES

C2: Osteoligamentous lesion

C2.1: Luxation fracture with fracture in posterior elements

- (1) Arch and/or processus spinosus**
- (2) Facet fracture**
- (3) (1) + (2) combined**

C2.2: Wedge fracture of the vertebra with rupture of the posterior ligament complex

- (1) Osteoligamentous**
- (2) Solely ligamentous**

C2.3: Vertebral body fracture (fissure in anterior superior portion + posterior fragment with dislocation greater than 3 mm in the spinal canal) (tear drop fracture)

- (1) Osteoligamentous**
- (2) Solely ligamentous**

TYPES OF LOWER CERVICAL SPINE FRACTURES

C3: Solely or primarily ligamentous injury

C3.1: Solely luxation, unilaterally hooked

C3.2: Solely luxation, bilaterally hooked

**C3.3: Rupture of the disc and dorsal
luxation with rupture of
the posterior ligamentous
complex**

OCCIPITAL – ATLANTAL DISLOCATIONS

Considered rare, but may be underestimated due to high fatality rate.

MECHANISM OF INJURY

- Distraction with the neck hyperflexed.
- Associated with the rupture of anterior occipitoatlantal ligament, tectorial membrane and alar ligaments.
- The occipito-atlantal joints are disrupted with dislocation of the occipital condyles on the lateral masses of the atlas.

OCCIPITAL – ATLANTAL DISLOCATIONS

SUBGROUPS *(described by Traynelis et al)*

- **TYPE I** – involves anterior translation of the cranium relative to the cervical spine & is thought to be the most common variety (Fig: 1).
 - It is suspected when the ratio of the distance between the basion & the posterior arch of the atlas, & the opisthion & the anterior arch of C 1 is greater than 1 (with normal being 0.77)

OCCIPITAL – ATLANTAL DISLOCATIONS

SUBGROUPS *(described by Traynelis et al)*

- TYPE II A – consists of longitudinal distraction between occiput & the atlas.
- TYPE II B - involves vertical distraction between the occiput & atlas as well as between the atlas & axis.
- TYPE III – consist of posterior displacement of skull relative to the cervical spine.

OCCIPITAL CONDYLAR FRACTURES

- **First described by Bell in 1817.**
- **Considered rare.**
- **Should be suspected in patients sustaining closed head injuries with lower cranial nerve deficits & neck pain.**

OCCIPITAL CONDYLAR FRACTURES

Three types are described:

1. TYPE I – involves a nondisplaced comminuted condylar fracture which is believed to occur from an axial load impacting the occipital condyle into the lateral mass of C 1.
2. TYPE II – involves a fracture through the skull base extending into the occipital condyle.

OCCIPITAL CONDYLAR FRACTURES

Three types are described:

3. TYPE III – consists of an avulsion fracture of the condyle by the ipsilateral alar ligament (Fig : 2).

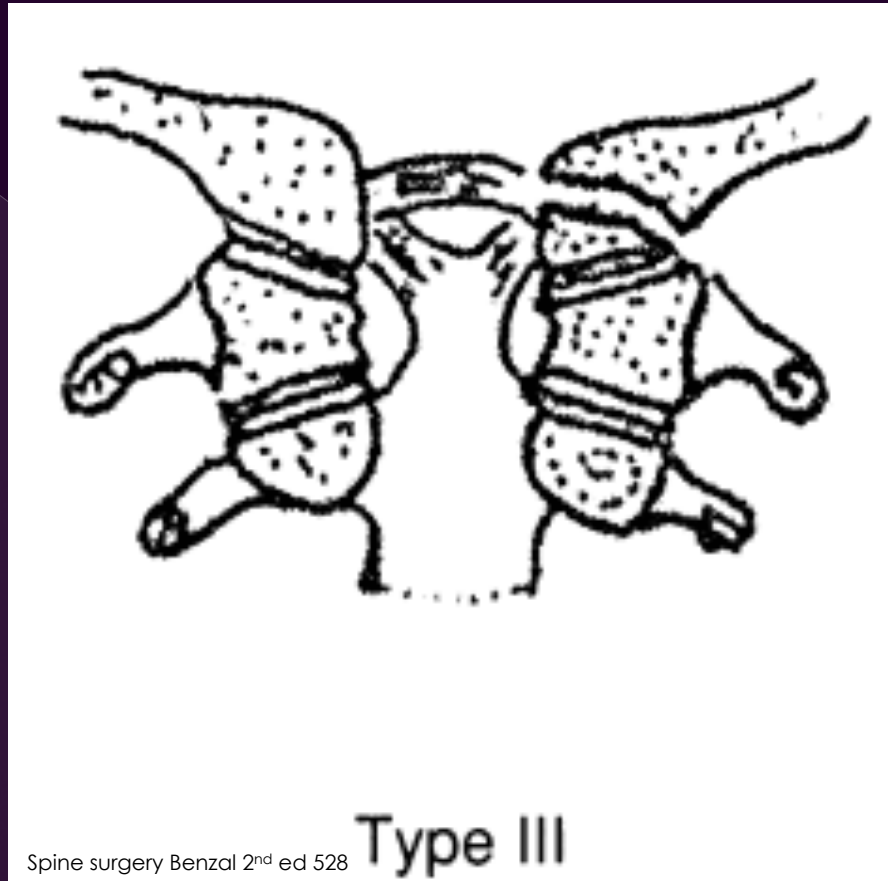
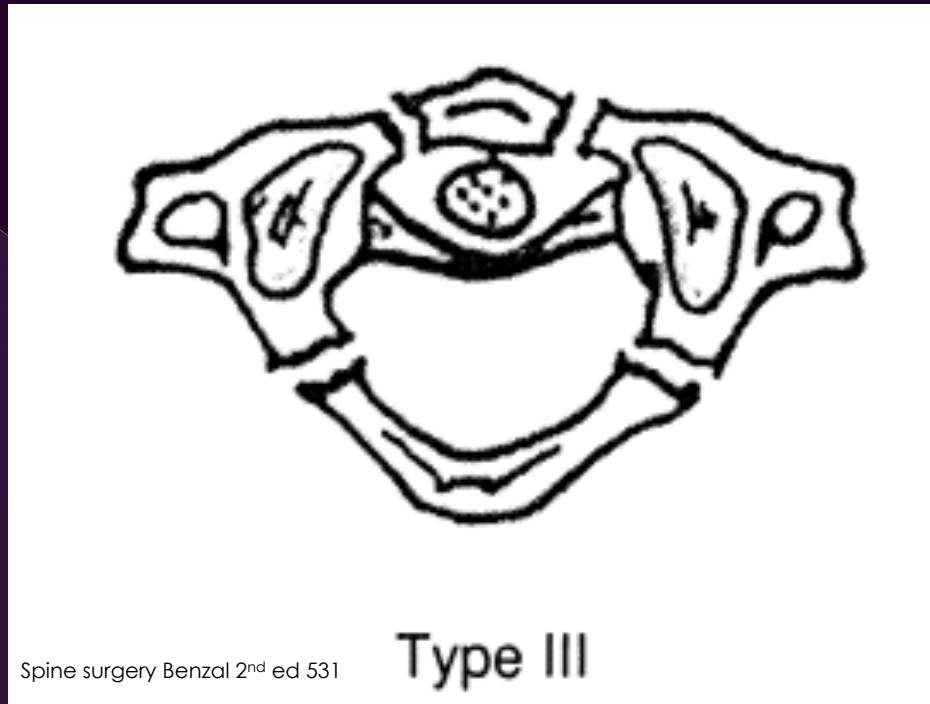


FIG 2: Type III occipital condyle fracture

C 1 ARCH FRACTURES – Jefferson Fracture

MECHANISM OF INJURY

- An axial load applied to the cranial vertex which drives the occipital condyles downward into the lateral masses of C1.
- The process displaces the masses laterally and causes fractures of the anterior and posterior arches, along with possible disruption of the transverse ligament. Quadruple fracture of all 4 aspects of the C1 ring occurs.



Jefferson fracture caused by a vertical (axial) compression mechanism is unstable. This fracture of all aspects of the C1 ring is associated with possible disruption of the transverse ligament of the atlas. Lateral projection may show a widened predental space and a fracture through the posterior arch of C1. Odontoid view shows displacement of the lateral masses of C1, allowing distinction of this fracture from a simple fracture of the posterior neural arch of C1.

ATLANTOAXIAL INSTABILITY

The various pathological processes that lead to atlantoaxial instability with the potential for damage to the cervical spinal cord are :

- Trauma
- Rheumatoid arthritis
- Neoplastic disease
- Basilar invagination
- Occipitalization of the atlas
- Os odontoideum
- Aplasia / Dysplasia of the dens
- Down's Syndrome
- Ankylosing spondylitis
- Retropharyngeal infections

ATLANTOAXIAL INSTABILITY

ATLANTOAXIAL SUBLUXATION

- When flexion occurs without a lateral or rotatory component at the upper cervical level, it can cause an anterior dislocation at the atlantoaxial joint if the transverse ligament is disrupted. Because this joint is near the skull, shearing forces also play a part in the mechanism causing this injury, as the skull grinds the C1-C2 complex in flexion. Since the transverse ligament is the main stabilizing force of the atlantoaxial joint, this injury is unstable. Neurologic injury may occur from cord compression between the odontoid and posterior arch of C1.
- Radiographically, this injury is suspected if the pre dental space is more than 3.0 mm (4.5 mm in children); axial CT is used to confirm the diagnosis. These injuries may require fusion of C1 and C2 for definitive management.

ATLANTOAXIAL INSTABILITY

ATLANTOAXIAL DISLOCATION

- When severe flexion or extension exists at the upper cervical level, atlanto-occipital dislocation may occur. Atlanto-occipital dislocation involves complete disruption of all ligamentous relationships between the occiput and the atlas. Death usually occurs immediately from stretching of the brainstem, which causes respiratory arrest.
- Radiographically, disassociation between the base of the occiput and the arch of C1 is seen. Cervical traction is absolutely contraindicated, since further stretching of the brainstem can occur.

ROTATORY SUBLUXATIONS

Far more common in children than in adults.

SUBGROUPS

(based on whether there is integrity of the transverse ligament)

- ❑ TYPE I – most common type. Transverse ligament is intact, & there is no anterior displacement of the atlas.
- ❑ TYPE II – rupture of transverse ligament with anterior translation of the anterior arch of the atlas up to 5 mm from the dens. Atlas rotation exceeds 35°.

ROTATORY SUBLUXATIONS

SUBGROUPS

- ❑ TYPE III – rupture of both transverse ligaments & alar ligaments with rotation of greater than 40 °, & anterior translation of the atlas relative to the dens of more than 5 mm.
- ❑ TYPE IV – rare lesion with retrodisplacement of the atlas relative to the axis.

ODONTOID FRACTURES

Injuries to the axis comprise up to 17 % of cervical spine injuries.

CLASSIFICATION (*Anderson & D'Alonzo, 1974*)

1. TYPE I : rarest of odontoid fractures & involve the tip of the odontoid process above the synchondrosis. They are generally stable & have a very low incidence of osseous non union.
2. TYPE II : common & involve the synchondrosis where the dens fuses with the body of C2. It is thought to disrupt the blood supply to the dens & leaves a small surface area for fracture healing. Non union rate range from 9 to 100%.

ODONTOID FRACTURES

CLASSIFICATION (*Anderson & D'Alonzo, 1974*)

3. TYPE III : includes fractures that extends into the body of the axis. Nonunion is not a major problem with these injuries because of a good blood supply and the greater amount of cancellous bone.

(Fig: 6)

SCIWORA Syndrome (Spinal Cord Injury w/o Radiologic Abnormality)

- Occurs most often in paediatric population.
- Accounts for up to 2/3 of severe cervical injuries in children < 8 years of age.
- Inherent elasticity in pediatric cervical spine can allow severe spinal cord injury to occur in absence of x-ray findings;

SCIWORA Syndrome

CAUSES

- transverse atlantal ligament injury - fracture through the cartilaginous end plates (which are not visualized by x-rays), may be among the causes of this injury;
- unrecognized interspinous ligamentous injury:
- in above 2 situations, flexion & extension views taken with pt awake and physician in attendance will demonstrate injury
- adult with acute traumatic disc prolapse

SCIWORA Syndrome

CAUSES

- cervical spondylosis
- C-spine trauma occurs w/ hyperextension injury to spine w/ vertebral canal whose diameter is already comprimised by spondylosis
- excessive anterior buckling of ligamentum flavum into canal already compromised by posterior vertebral body osteophytes probably is cause of central cord syndrome:
 - motor loss in arms > than in legs, & variable sensory loss;
 - typically, pts are managed nonsurgically w/ orthosis, & their neurologic status is carefully monitored

SCIWORA Syndrome

Radiographs

- diagnosis of exclusion:
- MRI may give a more anatomic diagnosis by showing hemorrhage or edema of the spinal cord;
- pseudosubluxation: anterior displacement may be up to 4 mm;

Treatment

Spine is immobilized for one to three weeks;

(Courtesy: Wheeless' Textbook of Orthopaedics)

LOCKED FACETS

- ◎ **Severe flexion injury – bilateral locked facet**

Disruption of ligaments.

C5 – C6, C6 – C7

65 -87% have complete quadriplegia

Closed or open reduction

MANAGEMENT OF CERVICAL SPINE INJURY

Prehospital Care

When a cervical spine injury is suspected, minimize neck movement during transport to the treating facility. Ideally, transport the patient on a backboard with a semirigid collar, with the neck stabilized on the sides of the head with sand bags or foam blocks taped from side to side (of the board), across the forehead.

MEDICAL MANAGEMENT

1. METHYLPREDNISOLONE

- As per National Acute Spinal Cord Injury Study (NASCIS) III
- Doses – 30 mg per kg body weight bolus dose over 15 minutes.



45 minutes pause



Maintenance dose @ 5.4 mg/kg / hour
for the next 23 hours

(if patient has presented within 3 hours of injury)

OR

For next 48 hours the above dose is to be maintained, if patient has presented after initial 3 hours

MEDICAL MANAGEMENT

- ◉ **GM 1 ganglioside**
- ◉ **Opiate antagonist**
- ◉ **Naloxone**
- ◉ **Calcium channel blockers**
- ◉ **Gacyclidine – amino acid receptor antagonist**
- ◉ **Anti oxidants & free radical scavenger - Tirilazad**

ALL THE ABOVE HAVE BEEN UNDERGOING TRIALS WITH DISAPPOINTING RESULTS

CERVICAL TRACTION

Cervical traction

- ⦿ creates a longitudinal pull along the cervical spine
- ⦿ restores normal anatomic alignment
- ⦿ provides stabilization
- ⦿ Most commonly used to treat injuries from the atlanto occipital joint to T1.

CERVICAL TRACTION

METHODS

- ⦿ **Head halter**
- ⦿ **Cranial tongs**
- ⦿ **Halo head ring**

CERVICAL TRACTION

HEAD HALTER TRACTION

INDICATIONS

- ✚ Cervical radiculopathy caused by a herniated disc or spondylosis.
- ✚ Cervical muscle spasm.

APPLICATION

- ⦿ Though they vary in design, head halter system consist of two pads, one placed under the chin & one under the occiput.

CERVICAL TRACTION

HEAD HALTER TRACTION

APPLICATION

- The Crile head halter is an exception, which has a pad under beneath the occiput & a padded forehead piece so that the chin is free.
- Patient is supine & is in the semiflexed position (flexed at the waist). Head of the bed is elevated at 30 - 40°, with the hips & knees flexed to about 45°.

CERVICAL TRACTION

HEAD HALTER TRACTION

APPLICATION

- ⦿ In outpatient treatment of patients with cervical spondylosis & muscle spasm, traction may be applied in sitting position. The amount of traction can be up to 45 lbs.
- ⦿ In supine position, the initial starting weight is usually 5 lb, increasing by a 5 lb increments upto a maximum of 15 lbs. Mostly 15 minutes of traction twice a day is prescribed.

CERVICAL TRACTION

HEAD HALTER TRACTION

RISKS

- ⦿ **Skin problems caused by pressure**
- ⦿ **↑ pain**
- ⦿ **Cervical radicular pain (LaBan et al)**

CERVICAL TRACTION

SKELETAL TRACTION

INDICATIONS

- ⦿ Serious injuries to the cervical spine to reduce a dislocation or fracture – dislocation.
- ⦿ To maintain the position of the cervical spine before & after operative fusion.
- ⦿ Occasionally for the treatment of cervical spondylosis with a severe nerve root compression syndrome.

CERVICAL TRACTION

SKELETAL TRACTION

INDICATIONS

- ⦿ Reduction of kyphosis following cervical laminectomy (Herman & Sonntag).

ADVANTAGES

- ⦿ Very efficient and can be regulated closely by the amount of weight applied.
- ⦿ Traction can be much greater than that tolerated with the halter
- ⦿ Can be applied continuously, 24 hrs a day over protracted periods of time.

CERVICAL TRACTION

SKELETAL TRACTION

APPLICATION

- ⦿ Should be commenced at 10-15 lbs.
- ⦿ Traction weights are usually increased every 30 to 60 minutes in 5 to 10 lb increments following radiographic evaluation.

CERVICAL TRACTION

SKELETAL TRACTION

GARDNER-WELLS TONGS

- ⦿ Easier to apply with self contained tension devices.
- ⦿ Readily applied using local anaesthesia.
- ⦿ Pin location is just below the equator of the skull & just above the ears (2-3 cm) in line with the external auditory meatus & the mastoid process.
- ⦿ Care must be taken to avoid excessive manipulation of the cervical spine.

CERVICAL TRACTION

SKELETAL TRACTION

CRANIAL HALO TRACTION

- ⦿ Introduced by Nickel, it provides a more efficient skeletal fixation to the skull.
- ⦿ Allows early patent ambulation.
- ⦿ Used to stabilize fractures & reduce fracture dislocations & dislocations of the upper & lower cervical spine following trauma, infection, inflammation & tumour invasion.

CERVICAL TRACTION

SKELETAL TRACTION

CRANIAL HALO TRACTION

- Provides good immobilization in the upper cervical spine for fractures of C1 & C2.

HALO IMMOBILIZATION OF CERVICAL SPINE INJURIES

The halo apparatus was first introduced by Perry & Nickel in 1959 as a traction apparatus to manage severe cranial instability secondary to poliomyelitis.

HALO IMMOBILIZATION OF CERVICAL SPINE INJURIES

INDICATIONS

A. Reduction of cervical

1. fractures

2. fracture – dislocations

3. subluxations

**B. Realignment of thoracic scoliosis & kyphosis
using halo femoral traction & halo pelvic
traction.**

HALO IMMOBILIZATION OF CERVICAL SPINE INJURIES

INDICATIONS

C. External fixation of unstable cervical spine in

- severe muscle paralysis**
- fracture dislocation**
- rheumatoid arthritis**
- primary / metastatic neoplastic disease**
- extensive laminectomy**
- following arthrodesis**
- osteomyelitis.**

TYPES OF CERVICAL SPINE INSTRUMENTATION

1. ANTERIOR INSTRUMENTATION

A. Upper C – spine

- Dens Screws

B. Lower C- spine

ANTERIOR IMPLANTS

- Locked plates
- Variable angle plates
- Dynamic plates
- Resorbable implants

ANTERIOR CAGES

- Threaded interbody cages
- Vertical mesh cages

C. Cervical disc arthroplasty systems

TYPES OF CERVICAL SPINE INSTRUMENTATION

2. POSTERIOR INSTRUMENTATION

A. Upper C- SPINE

OCCIPITOCERVICAL SYSTEMS

- Wiring systems
- Plating systems

C1 – C2 Instrumentation

- Gallie
- Brooks
- Magerl (C1 – C2 transarticular screws)
- Harms (C1 lateral mass with C2 pedicle screw)

TYPES OF CERVICAL SPINE INSTRUMENTATION

2. POSTERIOR INSTRUMENTATION

B. Lower C- SPINE

- Lateral mass plating/rodding systems
- Cervical pedicle screw/rod constructs
- Laminoplasty fixation systems
 - a. Mini plates
 - b. Suture anchors
- Wiring systems
 - i. Interspinous wiring
 - ii. Facet wiring
 - iii. Bohlman triple wiring

MANAGEMENT OF UPPER CERVICAL SPINAL INSTABILITY

ATLAS FRACTURES

- The treatment of most atlas fractures & lesser forms of C1- C2 is non surgical & depends on the type of atlas fracture & the presence of associated axis or other cervical vertebral body injuries.
- For isolated C1 fractures, Spence et al has laid down the criteria for appropriate therapy. If the sum of the spread of the lateral masses of C1 over C2 as determined by the AP C1-C2 x ray film exceeds 6.9 mm, the likelihood of transverse ligament disruption was more.

MANAGEMENT OF UPPER CERVICAL SPINAL INSTABILITY

ATLAS FRACTURES

- ◎ Spence et al concluded that injuries of that magnitude require a more aggressive approach to treatment & advocated surgical stabilization of C1 & C2.
- ◎ Isolated C1 fractures without rupture of the transverse ligament can be treated effectively with less rigid cervical support (typically a Philadelphia collar) for a duration of 8 – 12 weeks.

MANAGEMENT OF UPPER CERVICAL SPINAL INSTABILITY

ATLAS FRACTURES

- ◎ More rigid external immobilization and / or surgical stabilization for atlas fractures with a 6.9 mm or more dislocation of the lateral masses & those with transverse ligament disruption is recommended. Rigid external immobilization is established with the halo-vest immobilization device for 10 – 14 weeks.

MANAGEMENT OF UPPER CERVICAL SPINAL INSTABILITY

ATLAS FRACTURES

- ◎ Patients with marked C1-C2 instability with ligamentous disruption & those who fail rigid external immobilization are offered operative reduction, internal fixation, and fusion, typically a C1-C2 posterior wiring & fusion procedure.

MANAGEMENT OF UPPER CERVICAL SPINAL INSTABILITY

AXIS FRACTURES

- Several types of axis fractures are treated by non operative means. These include Hangman's fracture, odontoid type III fractures & miscellaneous axis fractures.

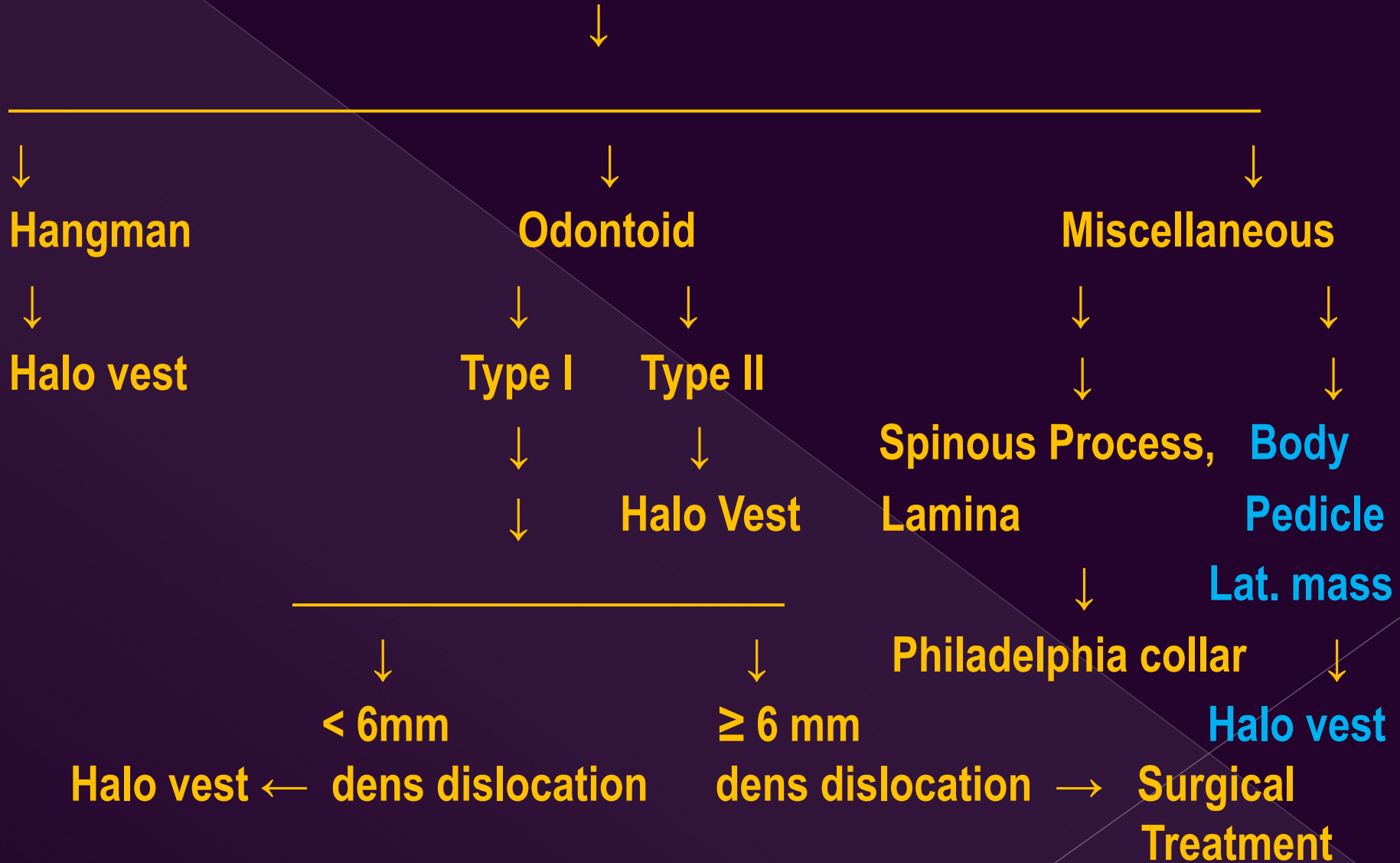
MANAGEMENT OF UPPER CERVICAL SPINAL INSTABILITY

AXIS FRACTURES

- Several types of axis fractures are treated by non operative means. These include Hangman's fracture, odontoid type III fractures & miscellaneous axis fractures.

AXIS FRACTURES

Isolated axis fractures



C1 - C2 COMBINATION FRACTURES

C1-C2 combination fractures



C1- Odontoid II fractures



< 6mm

dens dislocation

External immobilization

C1-C2 wiring/fusion



≥ 6 mm

dens dislocation

C1 ring

intact



Multiple C1 ring fracture



Occiput - C2 wiring / fusion



C1- odontoid III fractures

C1- Hangman fractures

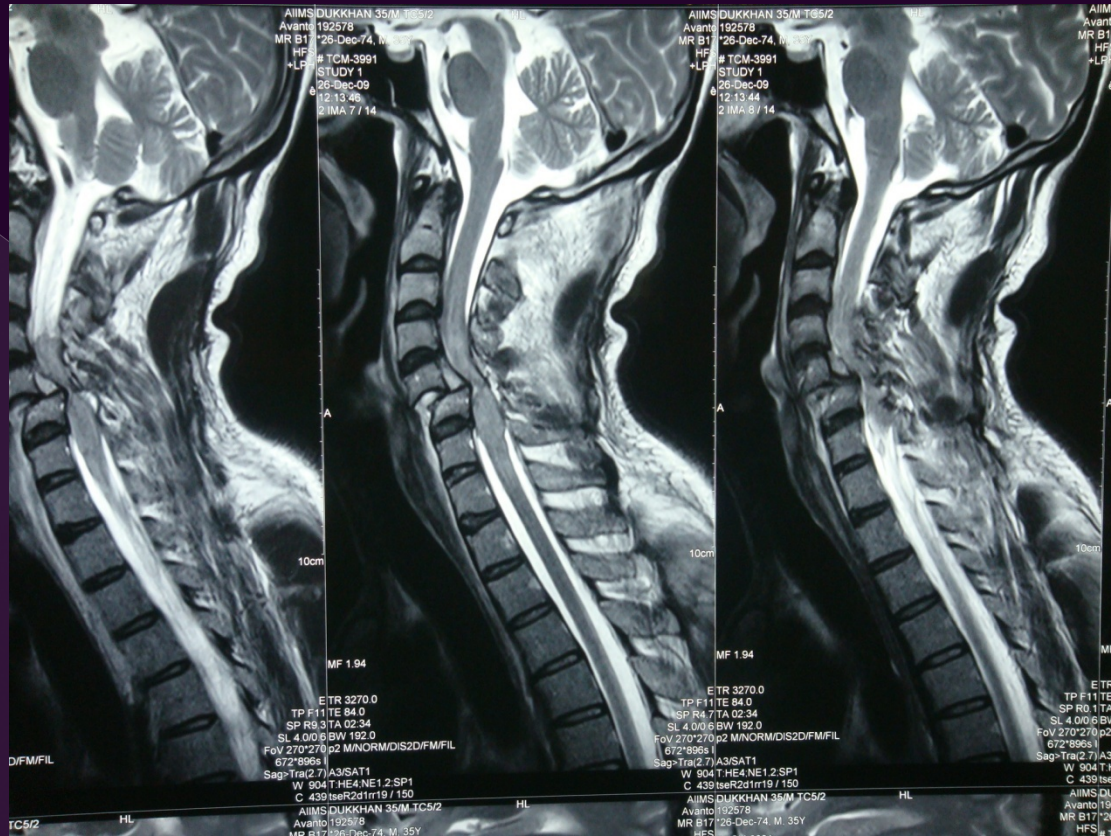C1- miscellaneous C2 fractures



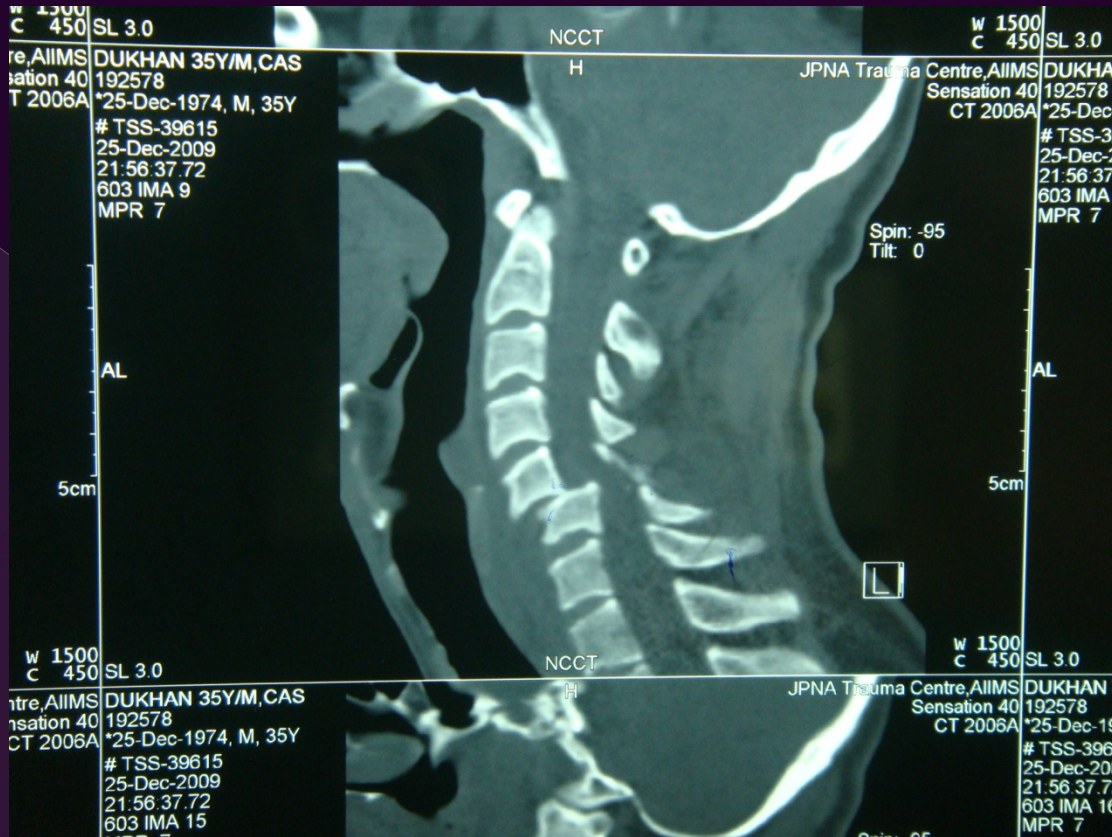External immobilization

THIRD CERVICAL VERTEBRA FRACTURES

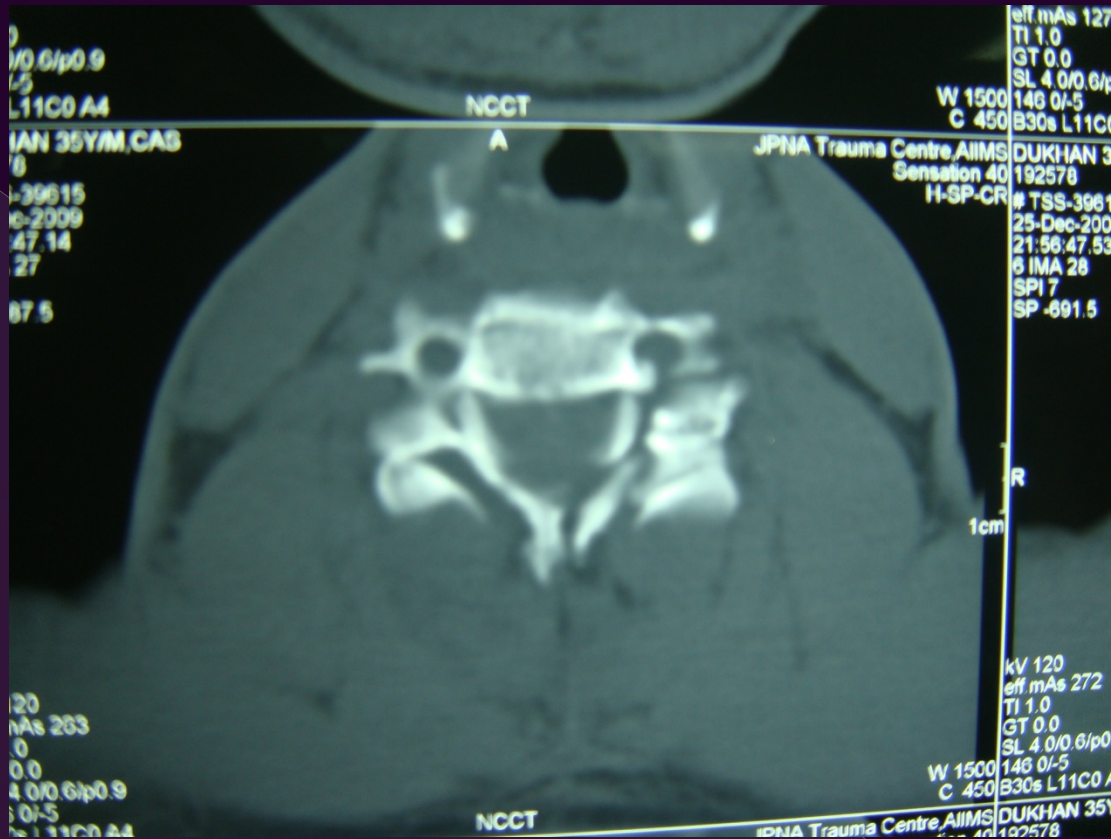
- **The treatment of C3 fractures must be individualized to the type of fracture and the type of associated fractures or fracture – dislocations.**



C 6 VERTEBRAL BODY RETROLISTHESIS WITH CORD COMPRESSION & CANAL COMPROMISE (MRI – SAGITTAL VIEW)



CT Cervical spine
(of the same patient of the previous slide)



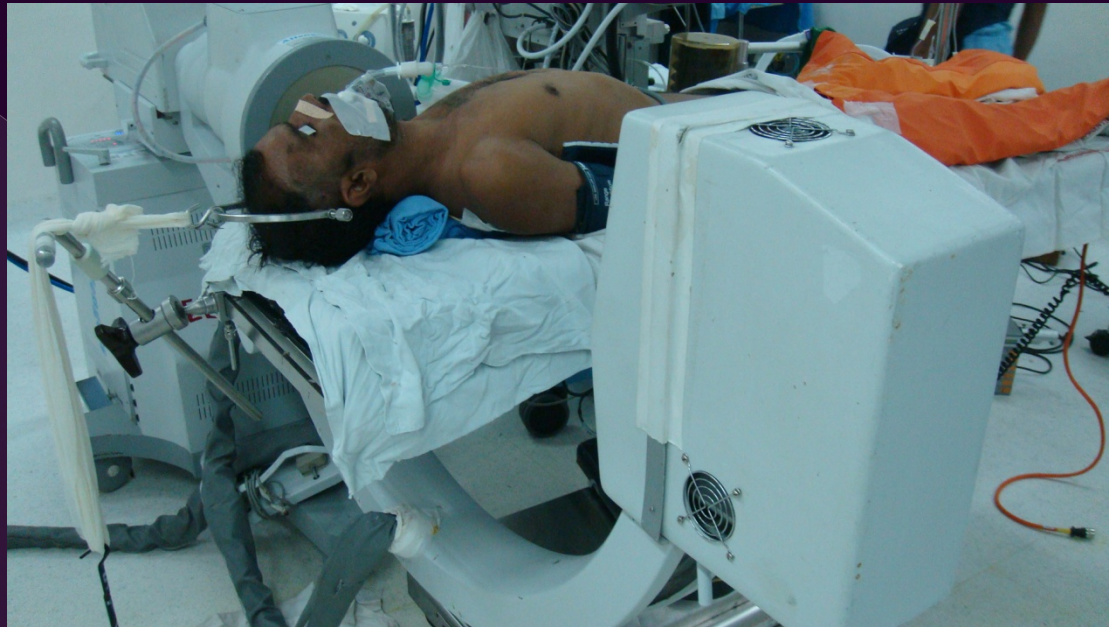AXIAL CT SHOWING FRACTURE C6 VERTEBRAL BODY AND POSTERIOR ELEMENTS

STABILIZATION OF CERVICAL SPINE

OPERATIVE PROCEDURES

◎ Preparation & Positioning

- Skeletal traction
- Supine position with head of the table elevated 10 - 15°
- Shoulders retracted
- Maintenance of normal lordotic curvature



POSITIONING OF PATIENT FOR ANTERIOR CERVICAL APPROACH

STABILIZATION OF CERVICAL SPINE

OPERATIVE PROCEDURES

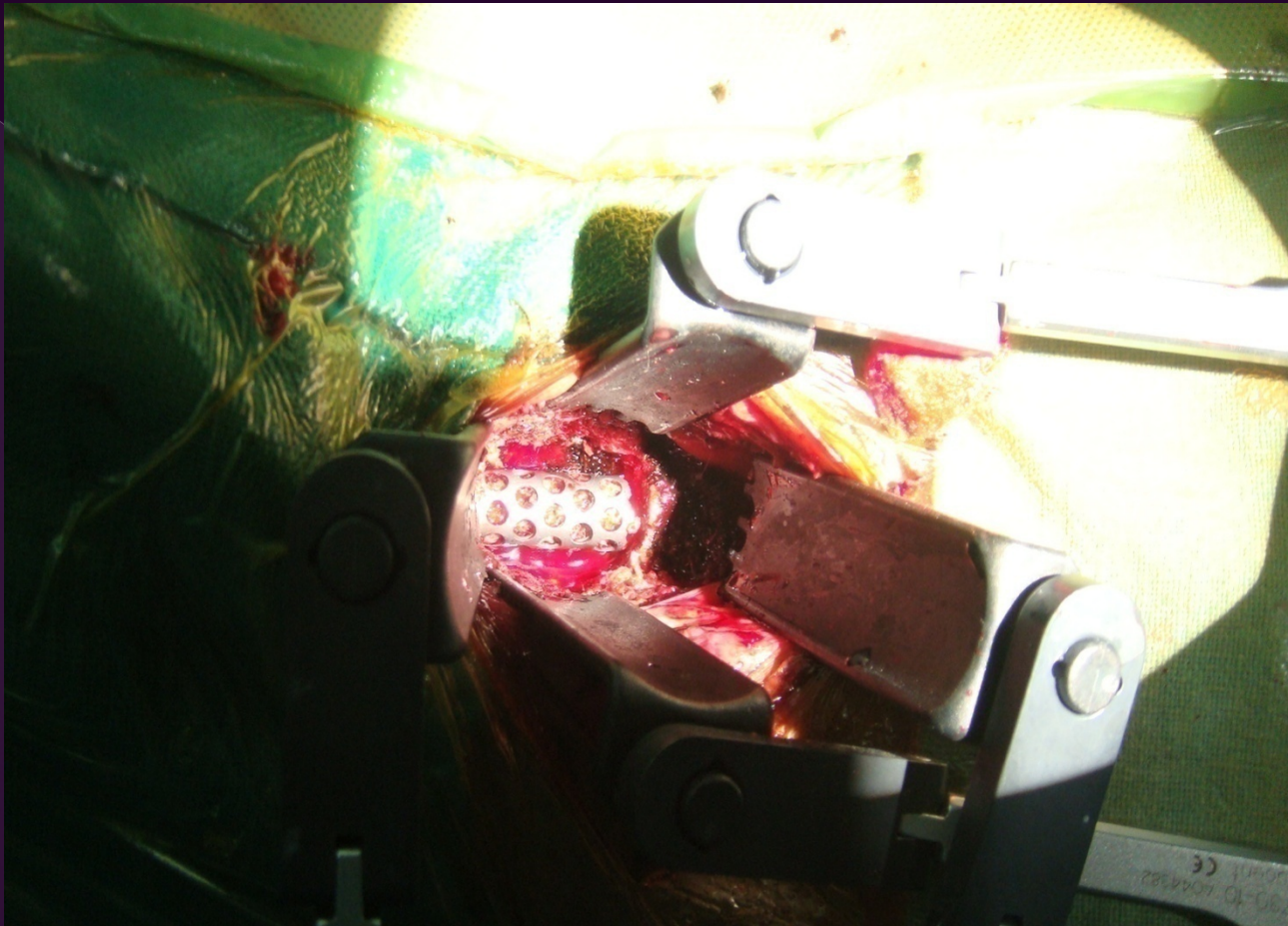
○ Skin incision

- transverse neck incision
- myocutaneous flap (skin & platysma)
- adequate exposure
- radioluscent blades for retraction preferred.

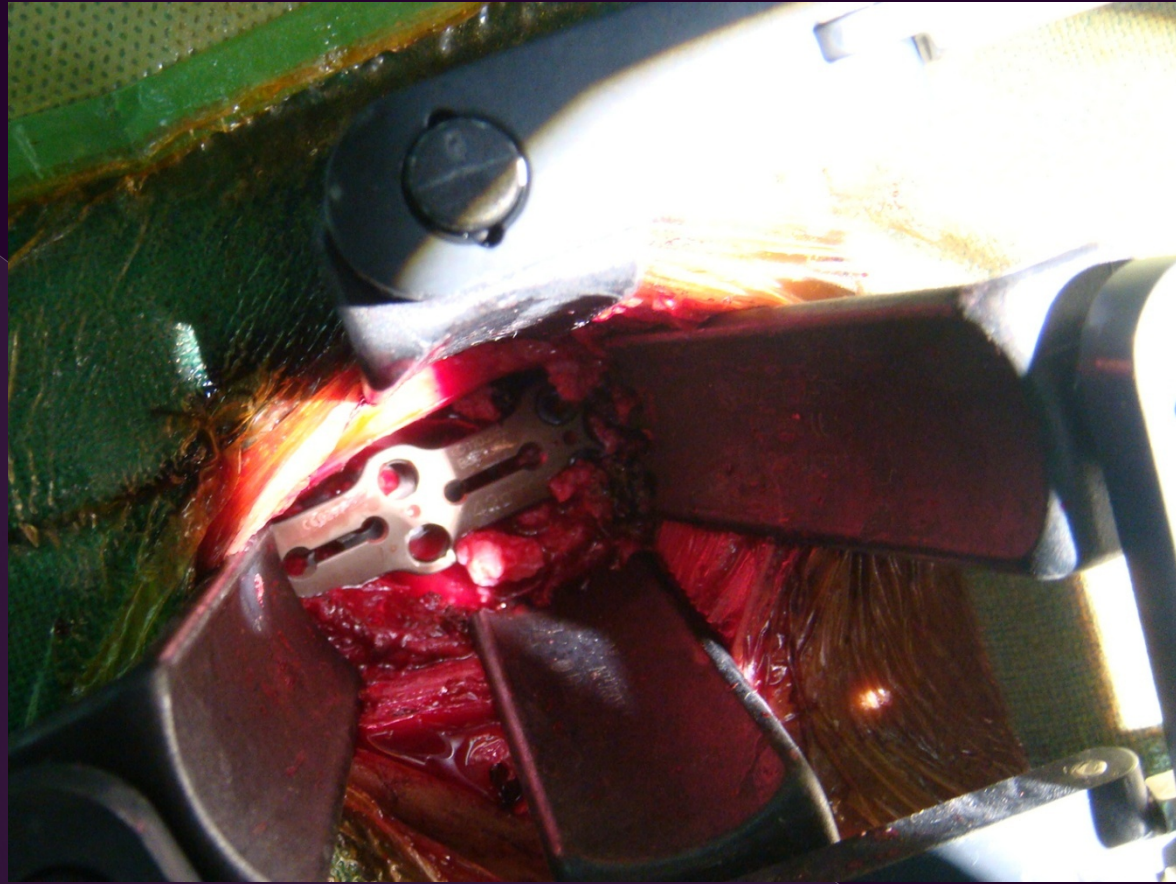
STABILIZATION OF CERVICAL SPINE

OPERATIVE PROCEDURES

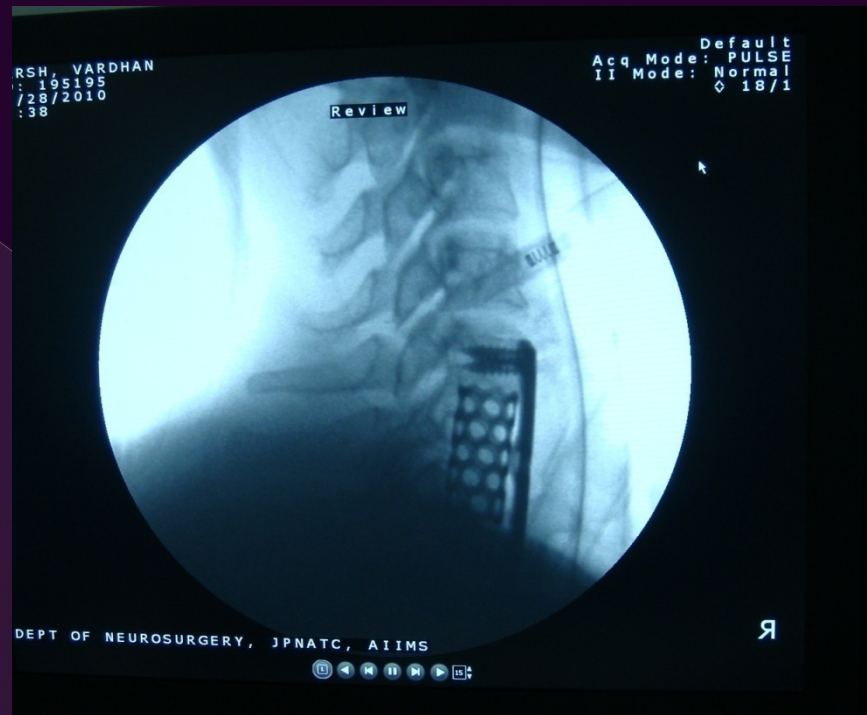
- ⦿ **Decompression & graft site preparation**
- ⦿ **Grafting**
 - **Autogenous bone graft**
 - **Tricorticate iliac crest bone graft for upto two level corpectomy.**
 - **Fibular graft for larger decompression**
 - **The graft should be rectangular**
- ⦿ **Plating**



**INTRA OPERATIVE PHOTOGRAPH SHOWING
METALLIC CAGE IMPLANT POST
CORPECTOMY**



PHOTOGRAPH SHOWING PLATING



**INTRA OPERATIVE RADIOGRAPH SHOWING
METALLIC CAGE WITH SCREWS AND PLATE IN
SITU**

SUBTOTAL & TOTAL BODY REPLACEMENT

- **Teardrop & anterior compression fractures – bone fragments removed along with disc above & below.**

- **Strut graft for complete corpectomy.**

COMPLCATIONS OF PLATING

CLINICAL COMPLICATIONS

- Infections
- Neurological injury

TECHNICAL COMPLICATIONS

- Screw loosening & plate failure

ANTERIOR STABILIZATION OF THE CERVICAL SPINE USING LOCKING PLATE SYSTEMS

It increases the stability of the initial fusion.

INDICATIONS

- **Treatment of anterior cervical instability**

COMPARISION AMONG THE THREE LOCKING PLATE SYSTEMS

TECHNICAL FEATURES	SYNTHESES	ORION	CODMAN
Material	Titanium	Titanium	Titanium
Locking Mechanism	Internal expansion screw	External covering screw	Cam lock
Screw diameter Core Thread	3.0 mm	2.4 mm	2.5mm
	4.35 mm	4.0 mm	4.5 mm
Rescue Screws	No	No	No
Screw Length	Fixed (14mm)	Variable (10-26 mm)	12 or 15 mm
Plate Shape	Flat	Lordotic	Lordotic
Medial entry angle	12°	6°	Variable
Cephalad/caudal angle	12°/ 0°	15°/15°	Variable
Screw construct	Convergent	Convergent	Variable

ANTERIOR STABILIZATION OF THE CERVICAL SPINE USING LOCKING PLATE SYSTEMS

PRECAUTIONS & COMPLICATIONS

- **Wound haematoma**
- **Vascular injury**
- **Oesophageal injury**
- **Superior or recurrent laryngeal nerve injury.**
- **Infection**
- **Long fusions are prone to screw breakage / pullout.**
- **Severe trauma may disrupt both the anterior & posterior elements, & anterior plating may be insufficient.**

THANK YOU